

## FUNCTIONAL OUTCOME ANALYSIS OF MODIFIED LATERAL SURGICAL APPROACH IN TOTAL HIP ARTHROPLASTY

K Jegadheesan<sup>1</sup>, Rajamani K<sup>2</sup>, V Shanmugapriya<sup>3</sup>

Received : 15/07/2023  
Received in revised form : 16/08/2023  
Accepted : 26/08/2023

**Keywords:**

Functional Outcome, Modified Lateral Surgical Approach, Total Hip Arthroplasty.

Corresponding Author:

**Dr. K Jegadheesan,**  
Email: dr.jegdeesh@gmail.com

DOI: 10.47009/jamp.2023.5.5.51

Source of Support: Nil,  
Conflict of Interest: None declared

*Int J Acad Med Pharm*  
2023; 5(5); 252-258



<sup>1</sup>Assistant Professor, Department of Orthopedic Surgery, Govt Medical College, Karur Tamil Nadu, India.

<sup>2</sup>Assistant Professor, Department of Orthopedic Surgery, Govt Medical College, Theni Tamil Nadu, India

<sup>3</sup>Assistant Professor, Department of Anatomy, Swamy Vivekanandha Medical College Hospital and Research Institute, Namakkal-637205, Tamil Nadu, India.

### Abstract

**Background:** With increased life expectancy these days and the resultant higher number of aged people leading active and independent lives, joint replacement surgeries are procedures that have increasingly been performed intending to improve quality of life for the population living with Orthopaedic conditions. The objective is to analyze the Functional Outcome of Modified Lateral surgical approach in total hip arthroplasty in Department of Orthopaedics and Traumatology, Chengalpattu Medical College and Hospital. **Materials and Methods:** This study was done in patients undergoing Total Hip Replacement in the Department of Orthopaedics and Traumatology, Chengalpattu Medical College Hospital, Chengalpattu. **Result:** The mean age of the patient was 56 years ranging from 39 years to 80 years with maximum occurrence in 61 to 70 years age group. The most common indication for surgery was fracture Neck of Femur. Out of 42 patients 40 patients had negative modified trendelenburg test, of 42 patients in our study the EMG recordings of the gluteus medius muscle on the operated hip were normal in all 42 cases. Functional outcome of the procedure was evaluated by following the Harris hip Score (Modified) showing excellent results in 13 (30%) diseased hips, good in 20 hips (47%) fair in 8 hips (21%), poor in 1 hip (2%). **Conclusion:** We conclude the modified lateral approach is a safe alternative to other approaches.

## INTRODUCTION

Despite the advancements seen in total hip replacement surgery over the last few decades, the selection of the best surgical approach is still controversial in literature, being so determined by individual preferences of the surgeon.

Total hip replacement is most commonly performed via a posterior or lateral approach. The relative merits of these two approaches are debated. A concern with the lateral approach is that it violates the abductor muscle mass, which can lead to permanent sequelae, including postoperative limp and weakness. This may occur either through denervation of the abductors or by damage to the superior gluteal nerve or by failure to reattach the muscle mass securely to the greater trochanter.

The modified lateral approach as described in this study offers predictable and easy access to the hip joint and provides excellent exposure of both Acetabular and proximal femoral regions.

1. The modified lateral approach differs from Hardinge (Direct Lateral) approach in several ways:
2. By splitting gluteus medius in 1/3 of its anterior, a large portion of the posterior 2/3 of the gluteus medius remains undisturbed at its point of insertion on the greater trochanter.
3. The superior extension of the abductor split is only 3 cm, maintaining a safe distance from the inferior branch of superior gluteal nerve.
4. A 'T' shaped incision was made on the anterior capsule with the vertical limb of the T along the intertrochanteric line and the horizontal limb across the anterior surface of the capsule to the Acetabular rim.
5. With the posterior capsule intact and the anterior capsule repaired, this modification gives soft tissue protection against dislocation.
6. The gluteus flap was repaired to prevent avulsion of the flap from the bone.
7. Finally the patient is placed in the lateral decubitus position (cf. supine in Hardinge

approach) which would allow direct visualization of the relevant anatomy.

Hence this study was conducted to analyze the Functional Outcome of Modified Lateral surgical approach into talhiparthroplasty in Department of Orthopaedics and Traumatology, Chengalpattu Medical College and Hospital.

## MATERIALS AND METHODS

This study was done in patients undergoing Total Hip Replacement from May 2019 to November 2020 in the Department of Orthopaedics and Traumatology, Chengalpattu Medical College Hospital, Chengalpattu. A total of 42 patients were included in the study out of which 22 were male and 20 were females.

### Inclusion Criteria

1. Patients above 35 years age
2. Patients with unstable hip
3. Patients with arthritic hip
4. Patients willing to give written informed consent

### Exclusion Criteria

1. Age less than 35 years
2. Infection
3. Patients With Neurological diseases
4. Patients with psychiatric illness
5. Revision total hip arthroplasty

Diagnosis included are chronic arthritis secondary to primary osteoarthritis, Avascular necrosis, inflammatory conditions namely rheumatoid arthritis, Neck of femur fracture and nonunion neck of femur fracture. All patients in this study underwent Total Hip Replacement using modified lateral approach.

### Preoperative Assessment

The patients were evaluated according to the modified Harris hip scoring system. The scores taken into account were of pain, function, range of motion and deformities. Also a mention of the limb length discrepancy and flexion contracture is made. The physical fitness of the patient undergoing a major surgery was assessed after taking Pre-operative informed consent. Physical examination included examination of spine and both lower extremities including opposite hip, both knees and foot. Trendelenburg test to assess the abductor musculature mechanism was done when possible. Neurovascular status of affected extremity was evaluated. Any occult infections like skin lesions, dental caries and urinary tract infections were identified and treated preoperatively.

### Roentgenographic evaluation

The goal of preoperative radiographic assessment is to confirm the diagnosis, to determine anatomic relationship of the femur and pelvis to allow for accurate restoration of joint anatomy and biomechanics. Standard pelvic roentgenogram AP view with both hips along with upper end femur, AP X-ray of hip in 15 degrees of internal rotation and

lateral X-ray of hip were taken. X-rays of spine and knees were also taken to know their status. Following features were noted,

Femur-Bone stock, medullary cavity, limb length discrepancy and neck profile. Acetabulum-Bone stock, floor, migration, protrusion, osteophytes and approximate cup size.

### Surgical Technique

The operative technique described here varies significantly from many previously described lateral approaches to the hip. Therefore, the approach will be described in some detail. Preoperative templating is carried out to estimate limb length inequality and approximate acetabular and femoral component sizes.

### Position

The patient is placed in the full lateral position on the operating table, one posterior post is placed just above the natal cleft and one against Pubic symphysis. [Figure 1]

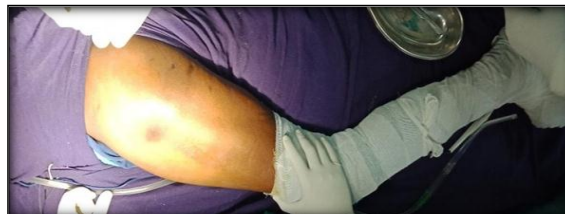

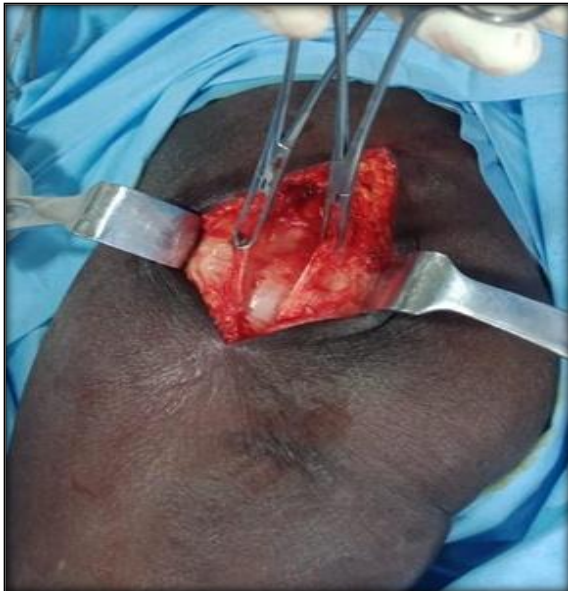Figure 1: Positioning of the patient

### Skin incision:

A straight lateral skin incision is made midway between the anterior and posterior border of the greater trochanter, centering on the tip of the trochanter measuring about 10-15 cm depending upon the weight of the patient.

### Deep dissection:

The fascia lata is incised in line with the skin incision, proximally fibers of gluteus maximus are split and retracted with a charnley's self-retaining retractor. In the proximal part of fascia lata, Gluteus Maximus insertion is encountered which is split in line with fascia lata. [Figure 2]

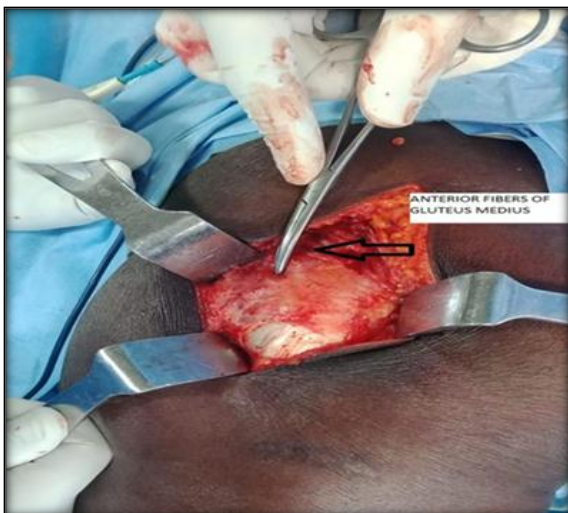

**Figure 2: Fascia lata incision**

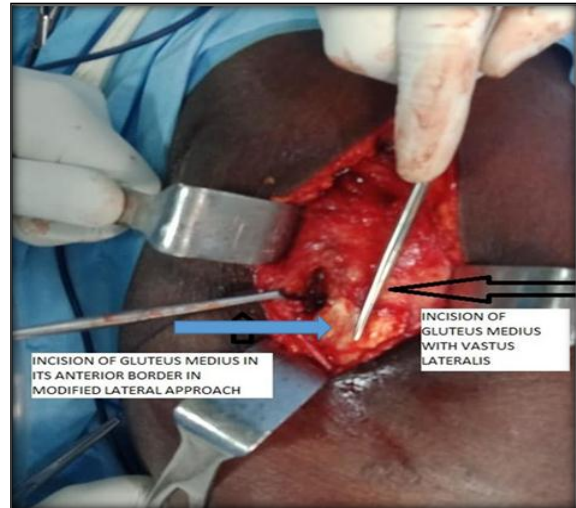
The trochanteric bursa is incised, anterior and posterior borders of the Gluteus Medius and the Vastuslateralis are identified.

### Elevation of the Conjoint Tendon

Deep blunt retractors are used to separate the muscle fibers of the gluteus medius at its anterior middle one-third junction, usually a layer of fat is visible deep to gluteus medius, this split is in the direction of the muscle fibers which makes anterior 45 degrees angulation to the skin incision, the split is not extended more than 3 cm cephalad to its insertion to protect the inferior branch of superior gluteal nerve. [Figure 3]



**Figure 3: Anterior border of Gluteus Medius**

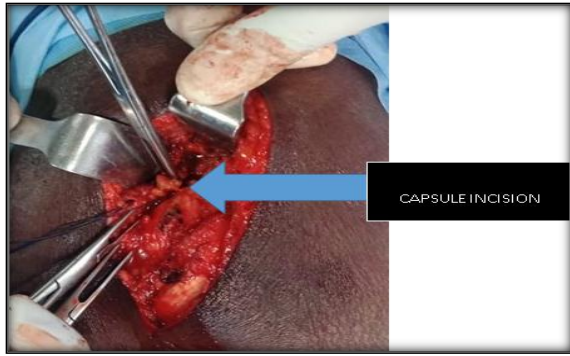


Splitting Gluteus Medius in anterior 1/3rd in modified lateral approach (blue arrow), splitting of Gluteus Medius along with vastuslateralis in Hardinge direct lateral approach (black arrow). Next blunt dissection is carried out through the anterior part of vastuslateralis passing down to the bone for about 4 cm. These fibres are divided superficially and then separated with self-retaining retractor, using diathermy the deeper fibres of vastuslateralis are split.

The transverse branch of the lateral circumflex artery in the vastuslateralis is usually encountered and can be easily cauterised. The now split portion of gluteus medius is connected to that of vastuslateralis over the greater trochanter at the junction of anterior third with posterior 2/3rd using electro cautery. With sharp dissection a flap is elevated consisting of the anterior part of the gluteus medius muscle with its underlying gluteus minimus and the anterior part of the vastuslateralis muscle

Capsular incision: The surgical plane between the glutei and capsule is marked by areolar tissue and dissection is carried out in this plane to the acetabular rim. The flap is retracted with a medially placed Hohmann's retractor placed extracapsularly above and below the neck of femur. The patient's leg is externally rotated to visualize the full length of the capsule with its overlying iliofemoral ligament. A 'T' shaped incision is made on the anterior capsule with vertical limb along the intertrochanteric line and the horizontal limb across the anterior surface of the capsule to the acetabular rim [Figure4]

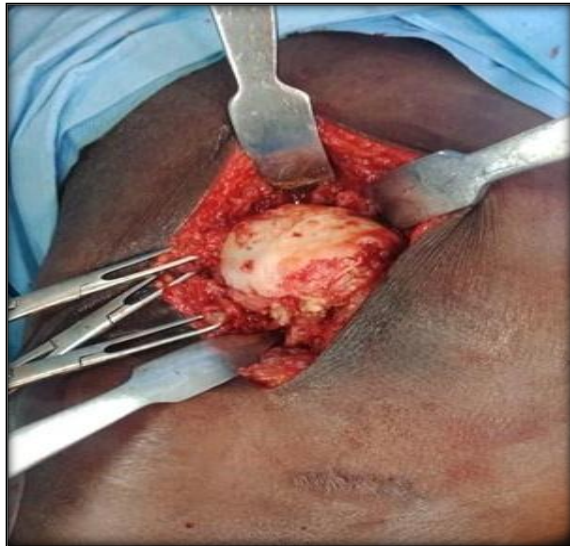



**Figure 4: Capsule incision**

### Dislocation of the Joint

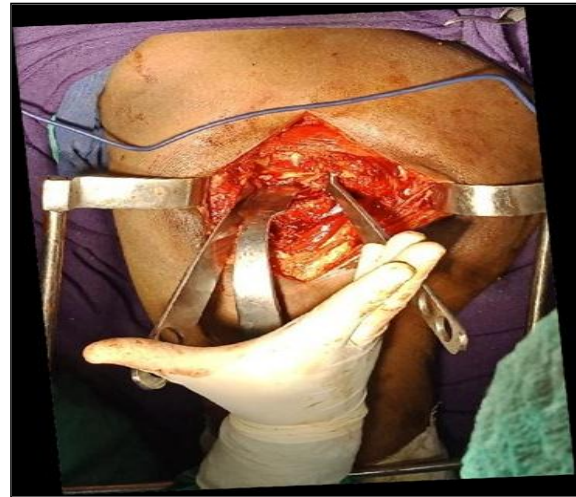At this stage the head of the femur is dislocated by flexion, adduction and external rotation. (Fig 16) The leg is then brought into sterile pouch to perform a femoral neck osteotomy (A corkscrew is used to deliver the head or neck osteotomised).



**Figure 5: Dislocation of the joint**

### Acetabular Exposure

The capsule is retained and is retracted using a self retaining retractor with one limb over the anterior capsule and the other over the trochanter, if the approach was not adequate an additional.

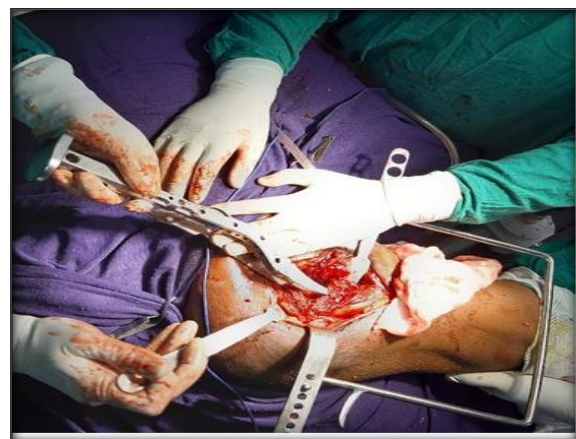

**Figure 6: Acetabular exposure**

For acetabular preparation, one Hohmann's retractor is placed anteriorly and the other in the acetabular notch beneath the transverse acetabular ligament, the limbus is excised throughout the circumference of the acetabulum. Acetabulum is prepared in the usual fashion using reamers to achieve concentric reaming. Trial acetabular prosthesis was then seated in to the acetabular fossa to assess the orientation of the cup to be seated. The optimal position of placement was 40 degree of abduction or inclination and 15 degree of ante version or forward flexion.

For femoral preparation, the leg is held perpendicular to the floor, care has to be taken not to damage the posterior fibres of the gluteus medius with the rasp while preparing the femoral shaft. This can also be avoided by retracting this muscle with blunt Hohmann's retractor. Preparation of the femoral canal was done using the appropriate reamers and broaches [Figure7].

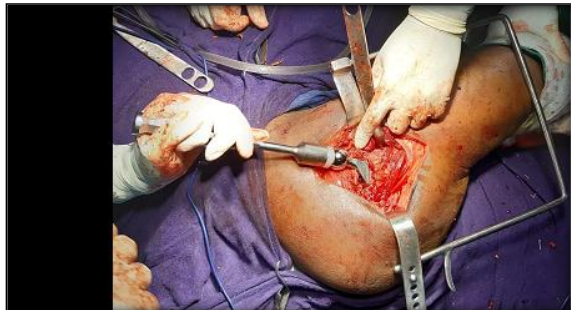Final implantation done after trial prosthesis was found to be stable and satisfactory.



**Figure 7: Femoral canal preparation**

Fixed suture length method was used intra operatively to assess the correction of limb length discrepancy. It is not necessary to excessively antevert or retrovert the acetabular or femoral components through this approach. In fact it is

generally acceptable to recreate the desired normal anatomy, that is approximately 15 degrees of acetabular version and 5-10 degrees of femoral anteversion. [Figure 8] When proper soft tissue tension is achieved, the stability of the joint can be demonstrated on flexion, adduction and internal rotation.



**Figure 8: Prosthesis insertion**

**Closure:** Careful attention was paid to the detail during closure of the muscular layers. “1” Vicryl was used to repair the capsule. The conjoint tendon flap (gluteus medius and minimus, vastuslateralis) was repaired to the greater trochanter condensation remnant, the split gluteus and vastus are approximated with “1” Vicryl stitches. The fascia lata, subcutaneous tissues and skin are closed in layers over drain.

**Postoperative Protocol:** The patients were nursed in post-operative ward with the hip positioned in approximately 15 degrees of abduction using abduction pillow in the immediate post-operative period. Bed exercises and limited mobilization was started on the first postoperative day.

Ambulation was permitted on the second postoperative day after drain removal and radiograph. Mobilization was started once the patients’ pain subsided; Strengthening and hip abduction exercises were taught to the patient. Patients were trained with crutch walking, and full weight bearing was allowed as tolerated by the patients. All patients treated with uncemented arthroplasties were allowed full weight bearing with crutches, beginning on the second postoperative day. Patients were followed up at 6 weeks, 10 weeks, 14 weeks, and 26 weeks regularly and then at every 6 months. Crutches were discarded at the end of 3 months. Clinical examination was done and assessed for tenderness.

## RESULTS

A prospective study was conducted to evaluate clinical, functional outcome in patients treated with primary total hip replacement for various indications. Both cemented, uncemented and hybrid total hip arthroplasty with various implant systems were used in this study, the minimum period of follow up was 6 months and maximum period of follow up was 18 months with average being 9 months.

The mean age of the patient was 56 years ranging from 39 years to 80 years with maximum occurrence in 61 to 70 years age group. In our study, Male predominance is about 52 % (22) out of 42 cases.

The most common indication for surgery was fracture Neck of Femur, the number being 22 (52%), other indications were arthritis hip, nonunion neck of femur fracture and avascular necrosis.

**Table 1: Indications for surgery**

Indications	No of patients	Distribution
FRACTURE NECK OF FEMUR	22	52.38%
SECONDARY OA	6	14.28%
A VN	5	11.90%
NON UNION NO FRACTURE	9	21.42 %

### Trendelenburg test (modified)

In our study out of 42 patients 40 patients had negative modified trendelenburg test, whereas 2 patients from secondary arthritis group had positive modified trendelenburg test.

**Table 2: Trendelenburg test (modified)**

Trendelenburg test	No of patients	Distribution
Negative	40	95.23%
Positive	2	4.76%

### EMG Study

Of 42 patients in our study the EMG recordings of the gluteus medius muscle on the operated hip were normal in all 42 cases, none of cases had denervation injuries.

**Table 3: Trendelenburg test and EMG results**

Test	No of patients	Positive	Distribution
Trendelenburg	42	2/42	4.76%
EMG	42	0/42	0

### HARRIS HIP SCORE (MODIFIED)

Functional outcome of the procedure was evaluated by following the Harris hip Score (Modified) showing excellent results in 13 (30%) diseased hips, good in 20 hips (47%) fair in 8 hips (21%), poor in 1 hip (2%).

**Table 4: HARRIS HIP SCORE (MODIFIED)**

Results	Noofhips	Distribution
Excellent	13	30.95%
Good	20	47.61 %
Fair	8	14.28%
Poor	1	2.38%

Out of 42 patients 39 diseased hips were treated with uncemented THR (90%), 3 hips (10%) were treated with hybrid THR.

### Complications

In our study out of 42 cases only 2 patients (4%) developed superficial wound infection managed with antibiotics and regular dressing, wound healed well subsequently without deep infection, there was no incidence of deep infection.

No incidence of prosthetic dislocation in any of our patients. Only 2 patients developed Heterotrophic ossification are being treated with tab. Indomethacin with regular follow up.

**Table 5: Complications**

Complications	No of patients	Distribution
Heterotrophicossification	2	4.76%
Loosening	-	-
Limb lengthdiscrepancy	-	-
Superficial infection	2	4.76%
Deep infection	-	-
Dislocation	-	-
Periprosthetic fracture	-	-

## DISCUSSION

Total hip replacement is a permanent method of relieving pain in the hip due to conditions damaging the joint surface. The aim of the surgery is to relive pain, at the same time to preserve motion and stability at the joint. Despite the advances in total hip arthroplasty, dislocation remains a frequent complication and has been reported to be 3-5% for primary osteoarthritis. This incidence can increase up to 18% for the total hip replacement done for fractured neck of femur.<sup>[1]</sup> Dislocation can occur even after good orientation of the components and proper tissue tension. Dislocations are still seen after posterior approach, even in the hands of an experienced surgeon.

Marcel Dudda, A gueleryuez, E Gautier ,ABusato,C Roeder (2010),<sup>[2]</sup> evaluated the risk factors for early dislocation after primary total hip arthroplasty (THA) in matched control study of 175 cases with dislocation and 651 controls, showed posterior approach was 6 fold more prone to dislocation than the anterolateral or straight lateral approach

V S Pai in a study,<sup>[3]</sup> of 35 consecutive Total hip replacement in displaced fracture neck of femur in the mobile independent elderly patient, performed by a single surgeon using modified lateral approach, at two years the overall early medical complication rate was 43%, there were no dislocations, eighty percent had a good clinical outcome.

There was no incidence of prosthetic dislocation in our study due to modified lateral approach and better placement of prosthesis.

Baker and Bitounis,<sup>[4]</sup> in their series conducted electrophysiological and clinical studies on patients who underwent total hip replacement by lateral, modified lateral, and posterior approaches. Studies were conducted 3 months following surgery. The Trendelenburg test was positive in 8 cases of direct lateral approach but in only one of each of modified lateral and posterior approaches. Denervation occurred in only 5 of the 28 hips with abductor weakness without significant statistical difference between the groups. In our study, of 42 patients who underwent EMG study on Gluteus medius, denervation was not observed in any of our patients. The modified direct lateral approach as described in this study retained Gluteus Medius without disturbing the muscle fibers and branches of superior gluteal nerve was not injured by taking precautions of avoiding dissection 3-4 cm beyond the tip of greater trochanter.

Trendelenburg test is a useful part of clinical examination and valuable in functional assessment. In our study out of 42 patients only 2 (4.76%) had positive Trendelenburg test. In a study of V.S.Pai (1996),<sup>[5]</sup> on 264 patients to assess the effects of lateral approaches to total hip arthroplasty on abductor weakness and significance of trendelenburg test when the criteria of Hard castle and Nade,<sup>[6]</sup> was applied, a positive response was seen in 19% in the trans trochanteric group, 15% in the Liverpool approach group and 18% in the Hardinge group. There was no statistical differences in the prevalence of the positive test in all three groups.

In our study 13 patients (30%) had excellent results, 20 patients (47%) had good results, 8 patients had (19%) fair results. Our results using this modified lateral approach are consistent with most other studies. The most common indication for surgery in our study was displaced neck of femur fracture in elderly active patients.

In a study done by Richard Blomfeldt et al,<sup>[3]</sup> on 84 patients he compared results of displaced femoral neck fracture treated with primary hip replacement with secondary hip replacement done for failed internal fixation with 2 year follow up. Author concluded that a secondary THR after a failed fixation results in inferior hip function compared to primary THR for displaced neck of femur fracture in the elderly active patient. Other indications in our study were nonunion neck of femur fracture, secondary osteoarthritis hip and avascular necrosis of femoral head.

This approach gives easy access to hip joint and provides good visualization and orientation of both acetabular and proximal femoral areas. This helps in better placement of prosthesis and thereby reduces the rates of postoperative dislocations. The reported incidence of hip abductor strengths on operated and normal side is similar in the studies in the literature.<sup>[7,8]</sup> In this modified approach, the posterior capsule is left intact and the anterior capsule is repaired, thereby providing a soft tissue envelope around the joint. This may give additional stability against dislocation.

## CONCLUSION

Modified lateral approach as described in this study offers predictable and easy access to the hip joint and provides excellent exposure to both acetabulum and proximal femur. This helps in better placement of the prosthesis. Dislocation is very rare and postoperative limp is not a major problem. The postoperative strength of the abductors of the operated side was comparable to that on the non-operated side and functionally. There was no incidence of superior gluteal nerve denervation. Due to preservation of posterior capsule and suturing of the anterior capsule and conjoint tendon, good soft tissue cover is provided anteriorly and postoperative dislocation is highly unlikely.

## REFERENCES

1. Svenson O, Skold S, Blomgren G: Integrity of the gluteus medius after trans gluteal approach in total hip arthroplasty. *J Arthroplasty* 5:57, 1990
2. Pai VS, Ardern D, Wilson N Fractured neck of femur In the mobile independent patient. *J Orthop Surg.* 2003 Dec;11(2):123-- 8
3. Richard Blomfeldt et al. *J Bone Joint Surg Am* 2005 Aug;87(8):1000-1005. Hastings DE, Sullivan JM, Colton CL: The hip. p 1. In Colton CL, Hall AJ (eds): *Atlas of Orthopaedic surgical approaches*. Butterworth & Heinemann, Oxford, UK, 1991
4. Baker AS, Bitounis VC. Abductor function after total hip replacement. *An electromyographic and clinical review. J Bone Joint Surg* 1989; 71-B: 47-50.
5. Pai V.S: Significance of the Trendelenburg test in total hip arthroplasty. Influence of lateral approaches. *J Arthroplasty.* 1996 Feb; 11(2):174-9.
6. Hard castle P, Nade S. The significance of the Trendelenburg test. *J Bone Joint Surg* 1985; 67-B: 741-6.
7. Mullikan BD, Rorabeck CH, Bourne RB, et al. A modified direct lateral approach in total hip arthroplasty: a comprehensive review. *J Arthroplasty* 1998; 13:737-47.
8. Pai VS. A modified direct lateral approach in total hip. *Arthroplasty J Orthop Surg* 2002; 10:35-9.